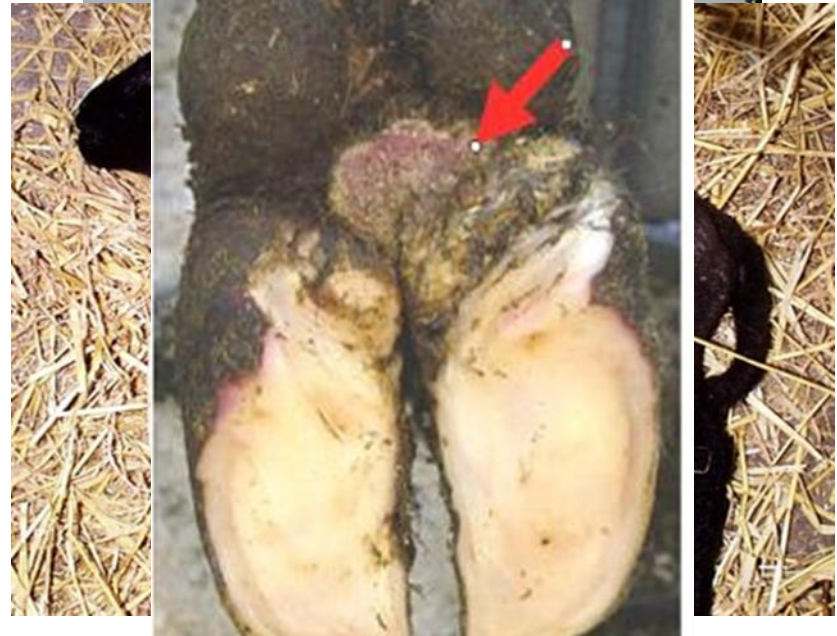

Disease Alert January 2017

- Digital dermatitis
- Abortion in ewes

James Aitken BSc BVetMed
MRCVS

Orchard Veterinary Group
Glastonbury

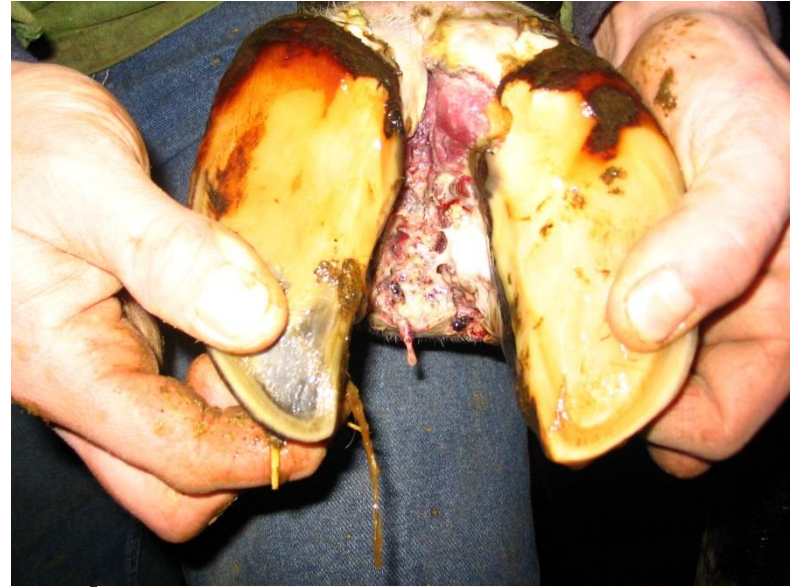

Thanks to our sponsors



Digital Dermatitis

- Treponeme infection of skin
- Present on at least 70% of farms
- On average 40% of cattle have some signs
- Can affect various sites
- Active lesions very painful
- Costs vary by farm, but likely to be considerable




Digital Dermatitis



- Individual treatment of painful active lesions
- Trim foot to rule out concurrent problems
- Clean and apply topical antibiotics
- Bandages must be changed daily
- Antibiotic footbaths now considered controversial

Digital Dermatitis

- Eradication currently impossible
- Biosecurity essential, even if already present on farm
- Ensure hygienic foot conditions
- Regular foot-bathing
- **Don't forget heifers and dry cows**



‘PREVENTION IS BETTER THAN CURE’

Plan for health with your vet

Get a veterinary health plan

Abortion in ewes

- Good record keeping essential
- Abortion rates above 2% should be investigated
- Common causes include
 - Toxoplasmosis
 - Chlamydia (EAE)
 - Campylobacter
 - Salmonella
 - Schmallenberg?



Toxoplasmosis

- Parasite of cats
- Older cats usually immune, kittens more likely to shed
- Vaccine available
- Deccoqinate during outbreak



Enzootic abortion (Chlamydia)



- Infected from ingestion of foetal fluids
- Carrier status
- Antibiotics of limited value
- Vaccine available
- Live lambs often very weak

'PREVENTION IS BETTER THAN CURE'

Plan for health with your vet

Get a veterinary health plan

Also keep an eye out for..



- Environmental mastitis
- Sole ulcers

Jobs for January

- Condition score ewes
- Check forage stocks and quality



‘PREVENTION IS BETTER THAN CURE’

Plan for health with your vet

Get a veterinary health plan

Thank you for watching

Please have a go at the clinical
quiz!