

Cattle and Sheep Clinical Library for Veterinarians

Over 2000 clinical videos & images with case notes


Over 300 common and rare diseases

Clinical signs & diagnostics in live animals and post-mortems

Copper deficiency

Case One

Swayback in lambs - this affected lamb has been weak on its hindlimbs since birth. This lamb attempts to move but can only move in a circle and drags its hindlimbs.




Weakness of pelvic limbs with reduced muscle tone and reflexes and muscle atrophy.



Malignant Catarrhal Fever

Case One

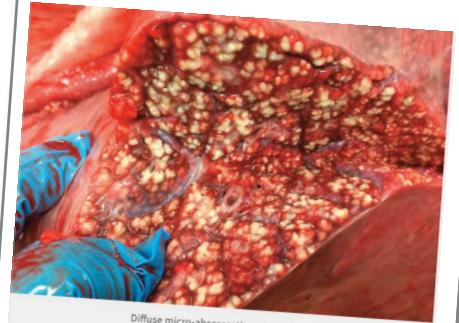
This beef steer presented depressed, anorexic and pyrexia. Corneal opacity was evident, as well as a nasal discharge, mucosal erosions and sloughing.



Corneal opacity, nasal discharge and mucosal sloughing.

Respiratory mycoplasma

Post mortem examination of a poor-doing calf (one of a group of 30) showing respiratory signs which were refractory to first-line antibiotics showed diffuse micro-abscessation of the lung tissue. Subsequent histology and culture confirmed *M. bovis* as the causative organism.



Diffuse micro-abscessation of the lungs

Try one-week free trial at

www.clinicallibrary.nadis.org.uk